DIGESTIVE SYSTEM

Digestive system

Parts of digestive system

Mouth , pharynx, esophagus, stomach, small intestine and large intestine.
Accessory glands are salivary glands (parotid, submandibular and sublingual glands), liver, pancrease and gall bladder.

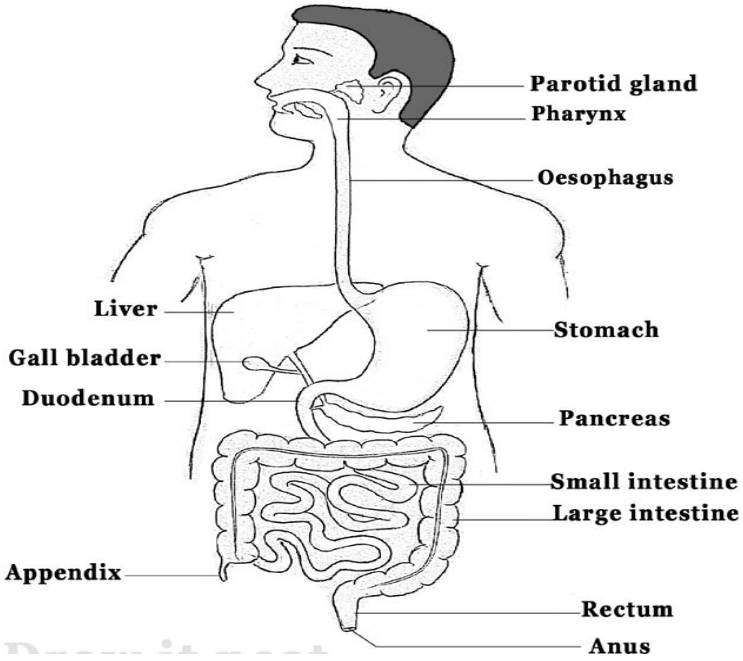

MOUTH

It is the first part of digestive system. It extends from lips to oropharyngeal isthmus. It is divided into two parts

1. Vestibule – it is a small space between lips, cheeks and gums with teeth.
2. Oral cavity proper – it is a large space inside the teeth and gums called oral cavity proper. It contain tongue.

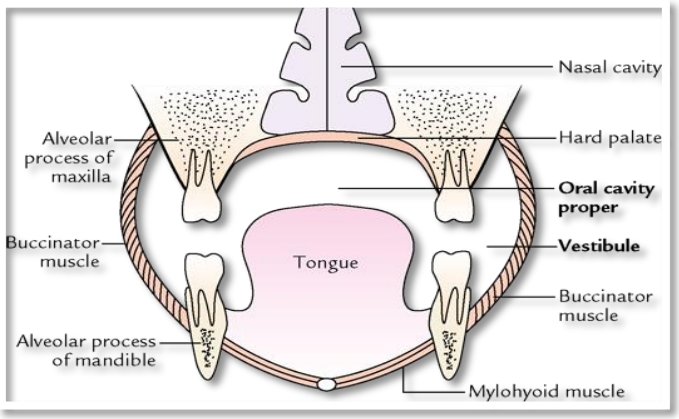

SALIVARY GLANDS

There are three pairs of large salivary glands. Namely parotid, submandibular and sublingual glands. The secretion of these glands are carried by their ducts in to the oral cavity, which is concerned with the digestion.

Distinguishing features

	Parotid gland	Submandibular gland	Sublingual gland
Location	Near the ear	Below the mandible	Below the tongue
Development	Ectodermal	Endodermal	Endodermal
Size	Largest (25gm)	Smaller (10 to 20gm)	Smallest (3 to 4gm)
Shape	Pyramidal	‘ J ‘ shaped	Almond
Duct and it site of opening in oral cavity	Parotid duct opens into the vestibule of mouth opposite to the crown of upper second molar tooth	Submandibular duct opens into the floor of mouth on summit of sublingual papillae at the side of frenulum of the tongue	Series of duct opens into the floor of the oral cavity on the sublingual fold
Secretomotor nerve supply	▪ Through lesser petrosal nerve ▪ Preganglionic fibers arise from the inferior salivatory nucleus ▪ Postganglionic from the otic ganglion	▪ Through chordatympani nerve ▪ Preganglionic fibers arise from the superior salivatory nucleus ▪ Postganglionic fibers arise from submandibular ganglion	•Through chordatympani nerve •Preganglionic fibers arise from the superior salivatory nucleus •Postganglionic fibers arise from submandibular ganglion
Nature of secretion	Serous	Both serous and mucous	Mucous

Microscopic structure of parotid gland

Largest salivary gland. It is compound tubulo acinar gland. It has well defined capsule, which extend into gland divide into lobes and lobules. It acini are purely serous. Serous acini are surrounded by myoepithelial cell. Well defined duct system is present.

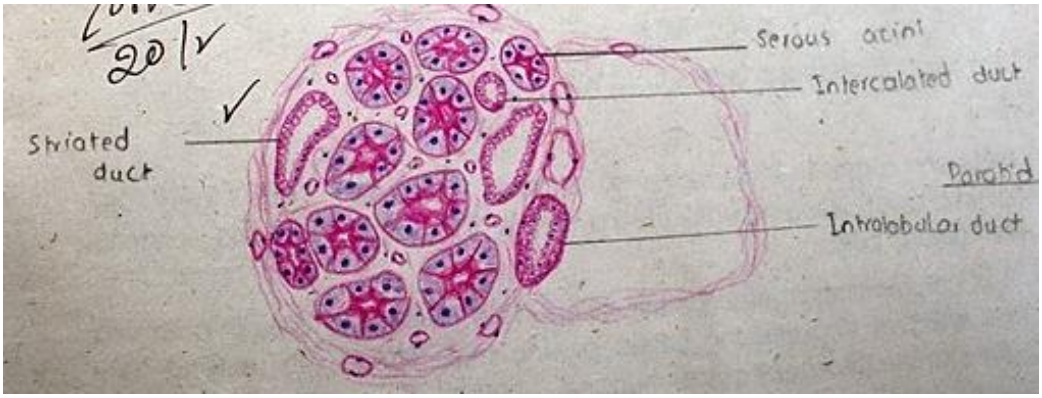

Microscopic structure of submandibular gland

It mixed salivary gland . It is a compound tubulo acinar gland. Well defined septa, divide gland into lobule. It consist both serous and mucous acini. Serous demilunes present.
Duct system : intercalated, striated, inter lobular.

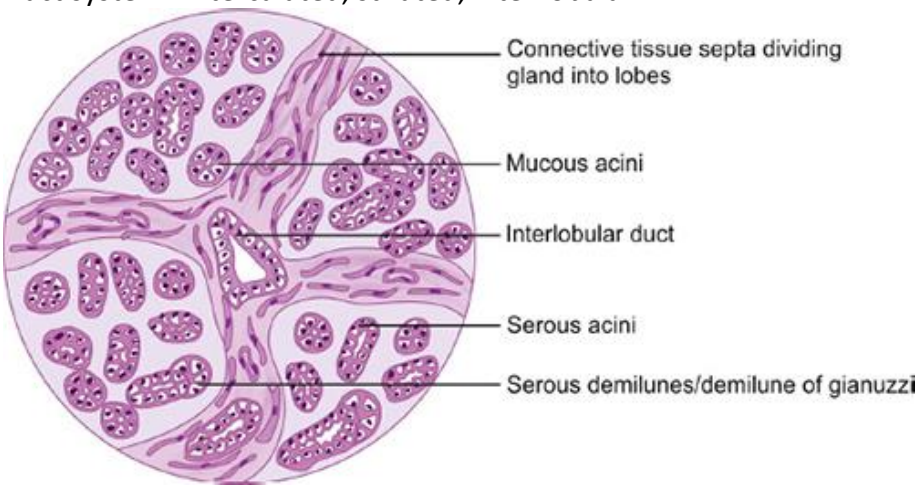

Microscopic structure of sublingual gland

Compound tubuloacinar acini : mucous acini is prominent. Ducts: interlobular duct are present. very few striated ducts are present.

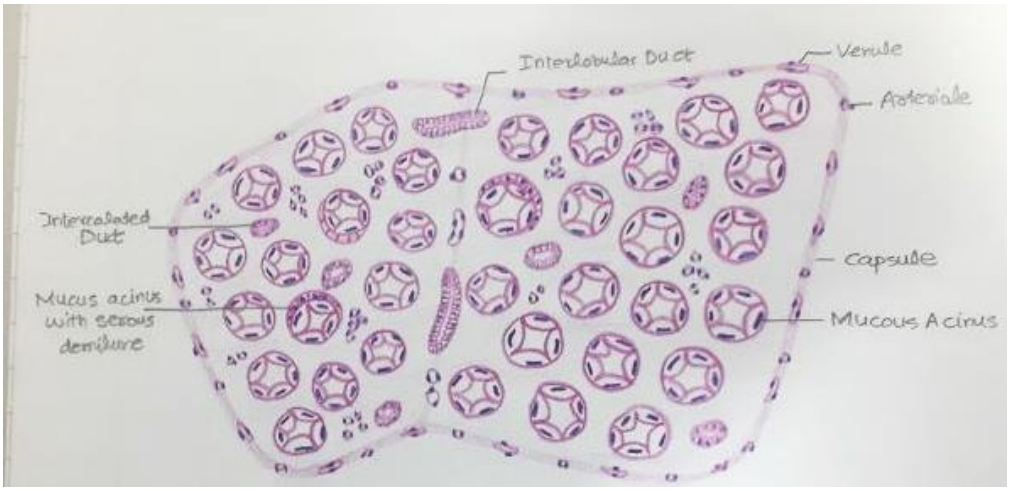

ESOPHAGUS

The oesophagus is a narrow muscular tube, forming the food passage between the pharynx and stomach. It extend from the lower part of the neck to the upper part of the abdomen. It is about 25 cm long. It is divided in to three parts – cervival, thoracic and abdominal parts.

Constrictions : There are four sites of constrictions or narrowing in the oesophagus. It is measured from the upper incisor teeth.

1. The first constriction at the distance of 15cm is produced by pharyngo-oesophageal junction.
2. The second constriction at a distance of 22.5cm is produced by the arch of aorta.
3. The third constrictionat a distance of 27.5cm is produced by left bronchus.
4. The fourth constriction at a distance of 40cm is at the oesophageal hiatus in the diaphragm.

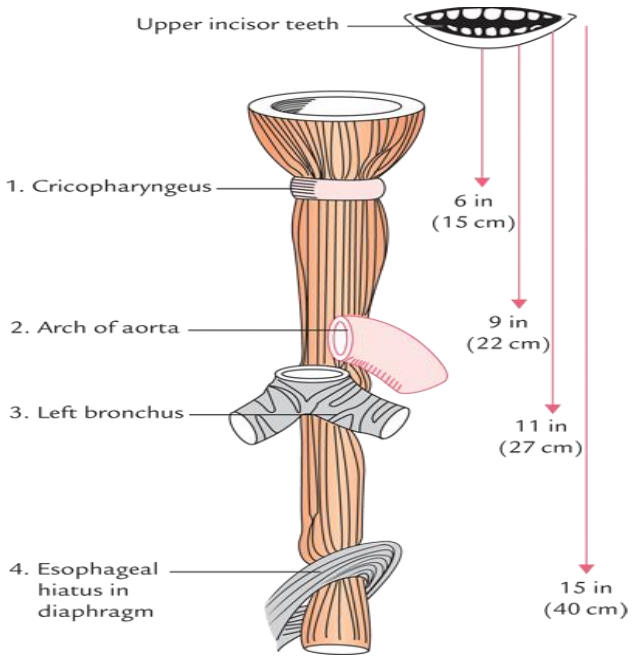

Relations

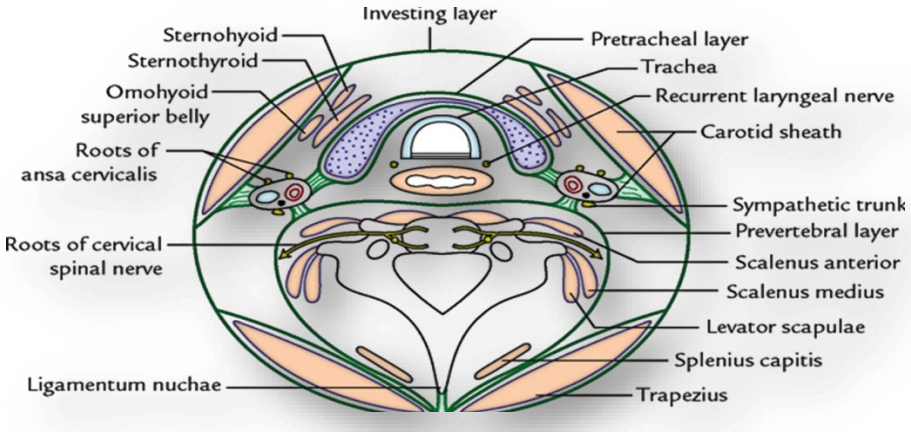

Anterior : trachea, aorta & its branches,recurrent larangeal nerve, phrenic nerve

Posteriorly : cervical, thoracic vertebrae

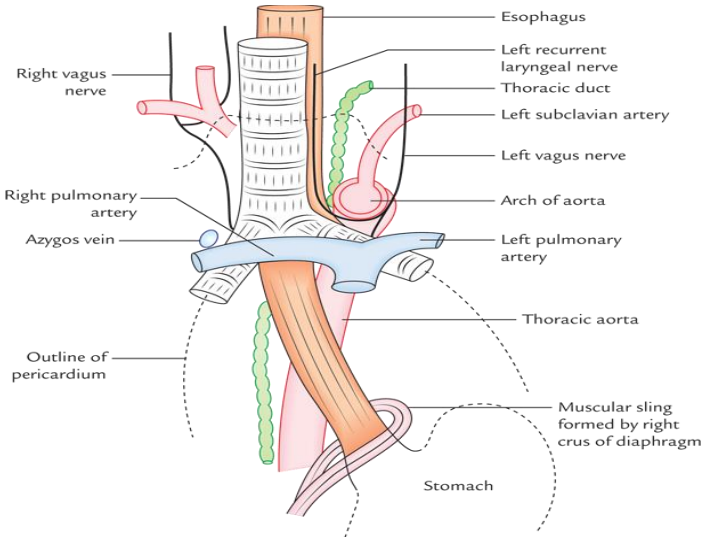

1. **Abdominal part**
   It is 1.25cm long. It enters the abdomen through the oesophageal opening of the diaphragm at T10 level.

- **Arterial supply**
  – inferior thyroid ateries.
  – oesophageal branches of thoracic aorta and bronchial arteries.
  - oesophageal branches of the left gastric artery and inferior phrenic artery
- **Venous drainage**
  inferior thyroid veins .
  drains azygos and hemiazygos veins.
  hemiazygos and left gastric vein
- **Nerve supply**
  Autonomic nerve system
  Microscopic structure

1. **Mucosa**

- Epithelium –thick non-keratinized stratified squamous epithelium .
- Lamina propria
- Muscularis mucosa- muscle fibers.

2. **Submucosa** - It is made up of loose connective tissue with blood vessels & nerves, mucous secreting oesophageal glands.
3. **Muscular layer** - These muscle is arranged in two layers – an outer longitudinal and an inner circular .
4. **Serosa / adventitia** - consist of loose connective tissue with blood vessels and nerves.

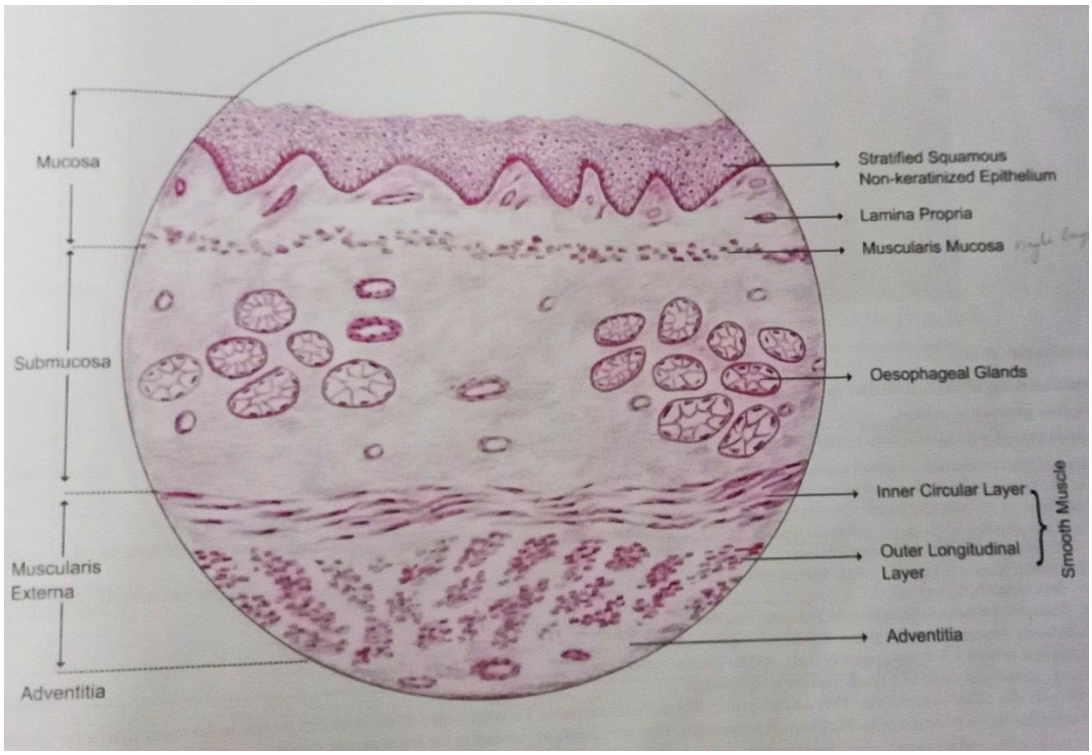

Applied anatomy

1. Dysphagia means difficulty in swallowing- due to aneurysm of arch of aorta, enlarged lymph nodes or carcinoma of oesophagus.
2. Carcinoma of oesophagus- the lower end of the oesophagus is prone to inflammation or ulceration by regurgitation of acid from the stomach. It is the commonest site of oesophageal carcinoma.

STOMACH

The stomach is a muscular bag forming the widest and most distensible part of the digestive tube. It connect lower end of esophagus to duodenum.

Location – occupying the epigastric, umbilical and left hypochondriac region

External features

The stomach has two orifices, two borders and 2 surfaces

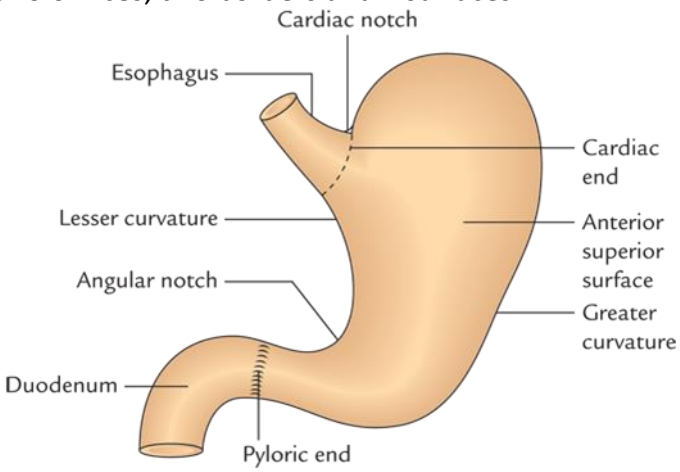

Two orifices

1. **Cardiac orifice** : it is joined by lower end of esophagus.
2. **Pyloric orifice** : It is joined by first part of duodenum, surface is indicated by a circular groove produced by the underlying pyloric sphincter and related by prepyloric vein.

Two curvatures

1. **Lesser curvature** : it is concave and form the right border of the stomach. It provides attachment to the lesser omentum. angular notch Is present
2. **Greater curvature** : it is convex and form the left border of the stomach. It provides attachments to the greater omentum, gastrosplenic ligament and gastrophrenic ligament. Its upper end present a notch called cardiac notch.(in the area oesophagus join with stomach)

Two surfaces

1. **Anterior surface** : face forward and upwards.
2. **Posterior surface** : face downward and backwards.

Subdivisions

Stomach is divided into two parts – cardiac and pyloric parts by an imaginary line drawn from angular notch to the greater curvature.

1. **Cardiac part** : the part above the line is called cardiac part. It is divided into- fundus and body

a. **Fundus** : Upper convex dome-shaped part situated above the horizontal line drawn from the cardiac notch to the greater curvature.

b. **Body** : it lies between the fundus and pyloric antrum.

2. **Pyloric parts** : it is divided into two parts, pyloric antrum and pyloric canal.

a. **Pyloric antrum** : It is about 7.5cm long

b. **Pyloric canal** : It is about 2.5 cm long and it is narrow and tubular.

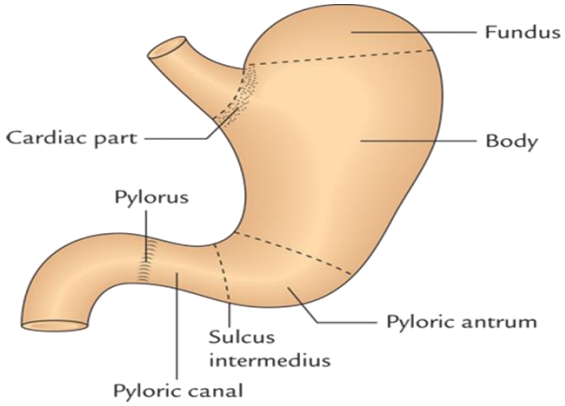

Relations

1. **Peritoneal relations**

The stomach is lined by peritoneum on both its surfaces.

a. Lesser curvature – lesser omentum.

b. Greater curvature- greater omentum, gastrosplenic ligament and gasterophrenic ligament.

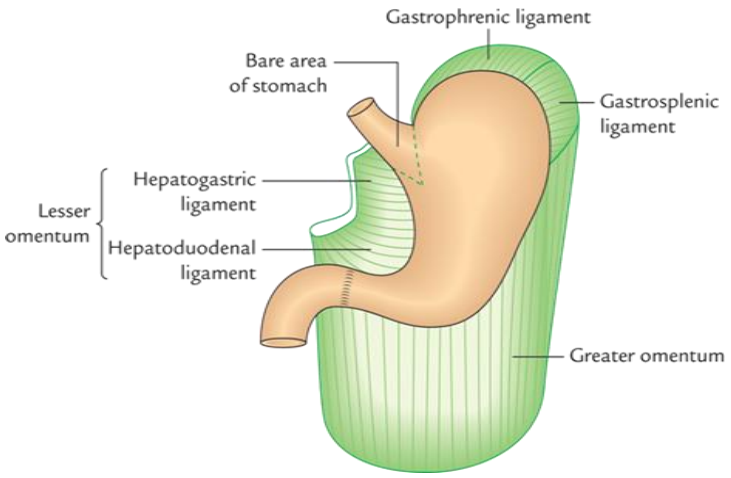

2. Visceral relations

a. Anterior surface - liver, diaphragm and anterior abdominal wall.

b. Posterior surface - structures forming stomach bed. They are diaphragm, left kidney, left suprarenal gland, pancreas,transverse mesocolon, splenic flexure of colon, splenic artery and spleen.

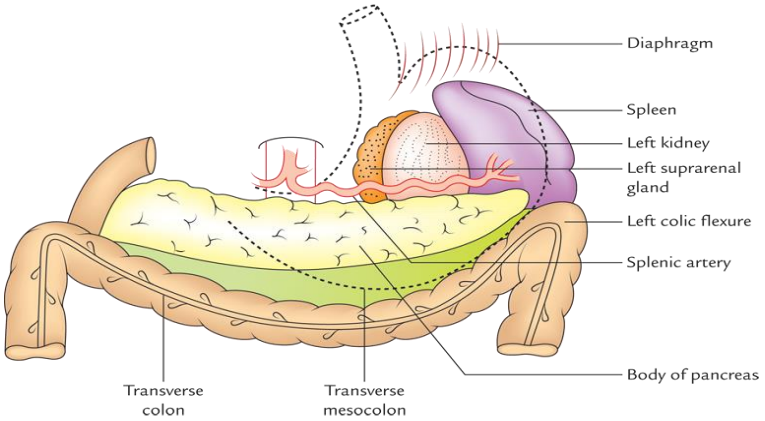

Interior of stomach

It is lined by mucous membrane and form folds called gastric rugae. On the mucosal surface there are numerous small depressions called gastric pit. The gastric glands are open into these pits.

Blood supply

Arterial supply

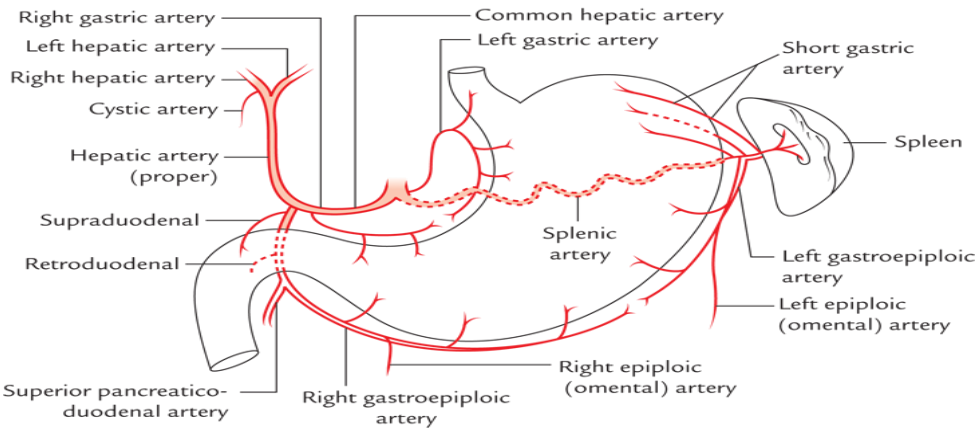

1. Left gastric artery- branch of celiac trunk.
2. Right gastric artery – branch of common hepatic artery.

3. Right gastero epiploic artery - a branch of gastero duodenal artery.
4. Left gasteroepiploic artery - branch of splenic artery.
5. Five to 7 short gastric artery – braches of splenic artery.

Venous drainage

The veins of stomach drains into the portal, superior mesenteric and splenic veins.

Lymphatic drainage : The stomach can be divided into four lymphatic territories.

First, divides the stomach into right 2/3rd and left 1/3rd by a line along its long axis. Then it divide right 2/3rd into upper 2/3rd (area 1) and lower 1/3rd (area 4) and left 1/3rd into upper 1/3rd (area 3) and lower 2/3rd (area 2).

Area 1→ is the largest area. Lymph from this area drained into left gastric nodes.

Area 2→ it includes pyloric antrum and pyloric canal along the greater curvature of the stomach. The lymph from this area drains into the right gastro epiploic nodes and pyloric nodes.

Area 3 → it drains into the pancreaticosplenic nodes.

Area 4→ it includes the pyloric antrum and pyloric canal along the lesser curvature of stomach. The lymph from this area is drained into hepatic and right gastric nodes.

The efferents from all these lymph node groups pass to coeliac nodes then into cysterna chyli.

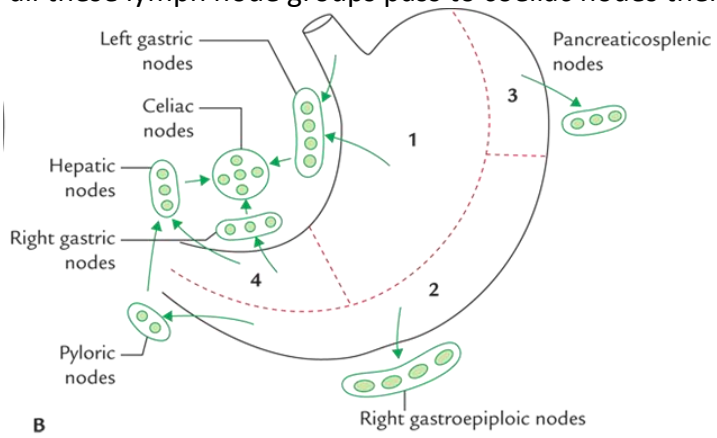

Nerve supply

The sympathetic nerves are derived from thoracic six to ten segments of spinal cord.

The parasympathetic nerves are derived from-the vagus.

Applied anatomy

1. Peptic ulcer can occur in the site of pepsin and HCl, namely the stomach, first part of duodenum and lower end of oesophagus.
2. Gastric carcinoma is common and occurs along the greater curvature.

Structure of stomach

General plan of git

Mucosa – is lined by simple columnar epithelium. Lamina propria filled with deep straight tubular glands with parietal and chief cells. Parietal cells also called oxyntic cells. They secrete gastric acid and intrinsic factor. Chief cells also called zymogen cells. They secrete pepsinogen.

1. Submucosa Muscularis externa – three layers of smooth muscle.
2. Serosa – membrane made of a simple squamous epithelium.

<u>Small intestine</u>

- Small intestine extend from pylorus to ileocecal junction.
- 6 meters long.
- Function : digestion & absorption.
- Parts- duodenum,jejanum,ileum

- Presence of circular mucosal folds or plica circularis/ valve of kerckring, these are permanent mucosal folds(absent in 1st part)
- Presence of villi & microvilli
- Intestinal glands or crypts of liberkuhn are simple tubular glands,secreate enzymes & mucous.
- **DUODENUM**

It is the shortest, widest and most fixed part of the small intestine.
Extend : from the pylorus to the duodenojejunal flexure. It is 'C'shaped and lies opposite to the L1 to L3 vertebrae. Closely related to head of pancreas
Length -25cm long.

Parts
First part – superior part.5cm long, it begins from the pyloric end of stomach & connect with the 2nd in the junction of superior duodenal flexure

.

Second part – desending part ,7.4 cm lo

Starts from duperior duodenal flexure ends at inferior duodenal flexure

- 3rd part – horizontal part
- 10 cm long
- Starts from inferior duodenal flexure & connect with fourth part of duodenum
- 4th part – ascending part. 2.5 cm long this part is mobile in nature

.

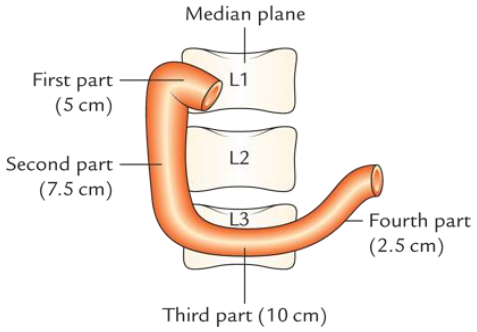

Peritoneal realtions : it is retroperitoneal, except as its two ends.
First part
It extends from pylorus to superior duodenojejunal flexure.

Visceral relations

Anterior-

liver & gall bladder,

transverse colon,small

intestine

,stomach,

lesser omentum

- **<u>Posterior relation</u>**
- Portal vein
- Bileduct
- Rt kidney & ureter
- Ivc
- psoas major
- **<u>Medially</u>** – head & uncinate process of pancreas
- **<u>Laterally</u>** hepatic flexure of colon
- **<u>Inferiorly</u>** – coils of ileium

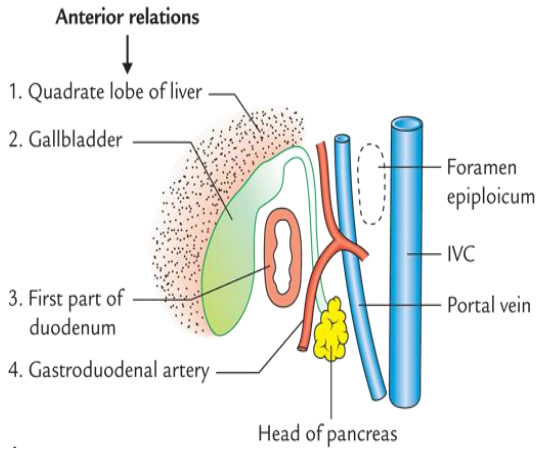

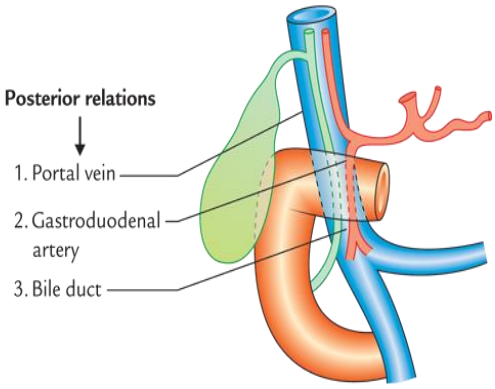

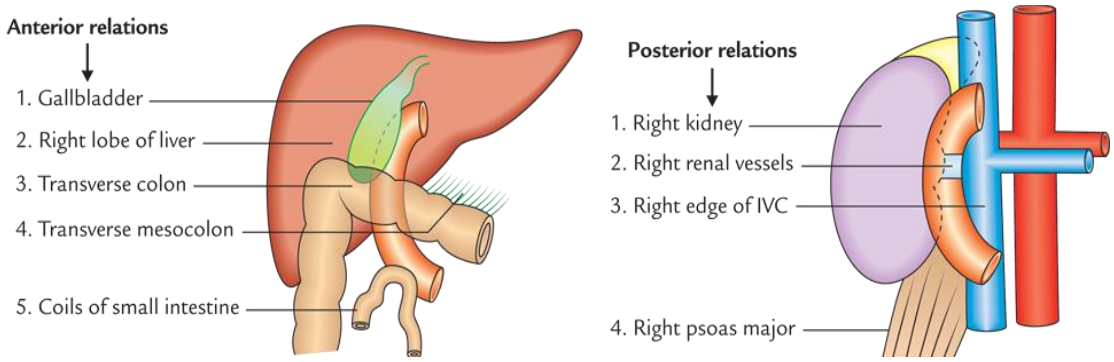

<u>Interior of the second part</u>

1. The major duodenal papilla : is an elevation present posteromedially, 8 to 10cm distal to pylorus. The hepatopancreatic ampulla opens at the summit of the papilla.
2. The minor duodenal papilla : is present 6 to 8 cm distal to the pylorus, and present the opening of the accessory pancreatic duct.

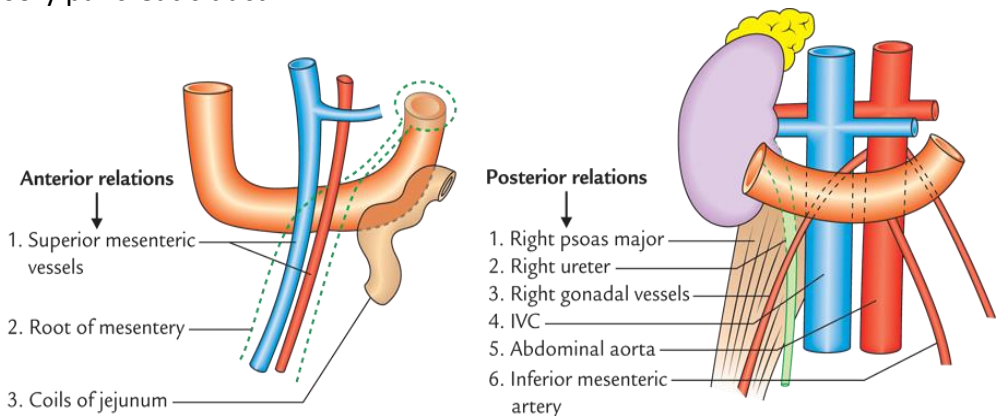

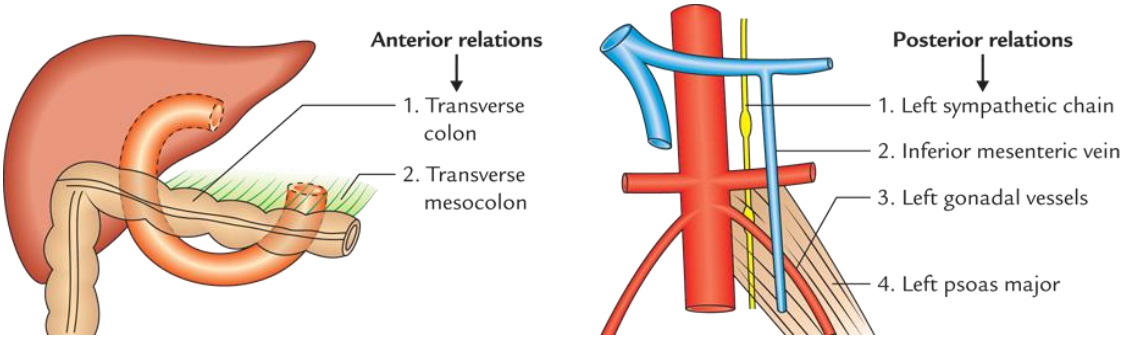

Arterial supply

Superior pancreaticoduodenal artery and inferior pancreaticoduodenal artery.

Venous drainage

The veins of the duodenum drainds into the splenic, superior mesenteric and poral vein.

Nerve supply

Sympathetic nerves- T9 and T10 spinal segments.

Parasympathetic – vagus.

Applied anatomy

Duodenal ulcer- the first part of the duodenum is the common site.

Structure of duodenum

1. **Mucosa** lined by simple columnar epithelium with microvilli and goblet cells. It contain folds called villi. Lamina propria filled with intestinal glands called crypts of Lieberkuhn.
2. **Submucosa** contain loose connective tissue with blood vessels, lymphatic and nerve fibers. It contain tubuloalveolar glands called Burnner's glands.
3. **Muscularis externa** contain inner circular, outer longitudinal smooth muscle.
4. **Serosa** is lined by squamous cells.

JEJUNUM AND ILIUM

Features	Jejunum	Ileum
cavity	Usually empty	loadaed
Thicknessof Walls	thicker	thinner
colour	Red, due to increased vascularity	paler
position	Coils occupy the umbilical region	Hypogastric and right iliac fossa
Plica circularis	Large well developed, numerous	Small in the superior part and absent in the terminal part
Presence of fat in mesentery	Less	more
Peyer's patches	Absent	Present

LARGE INTESTINE

The large intestine extends from the ileocecal junction to the anus. It is about 1½ m in length. The different parts of large intestine are-

- Caecum and vermiform appendix
- Ascending colon
- Transverse colon
- Descending colon
- Sigmoid colon
- Rectum Anal canal

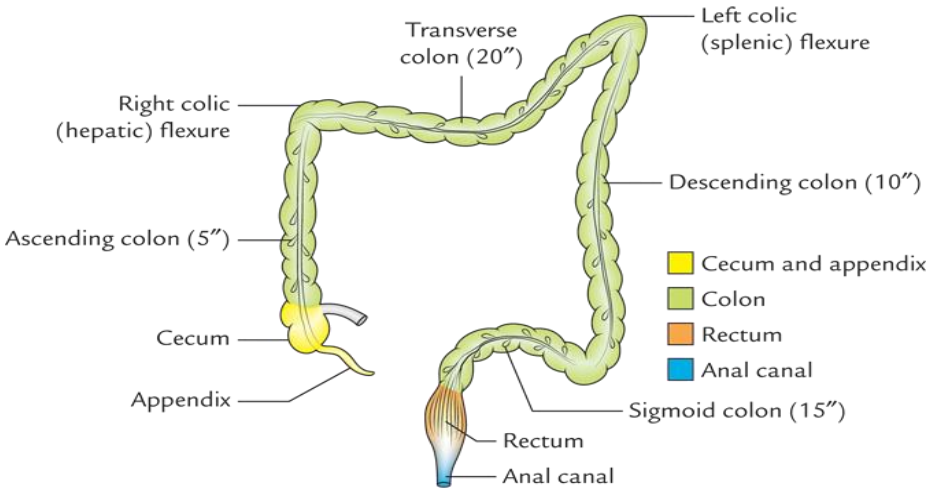

Features of large intestine

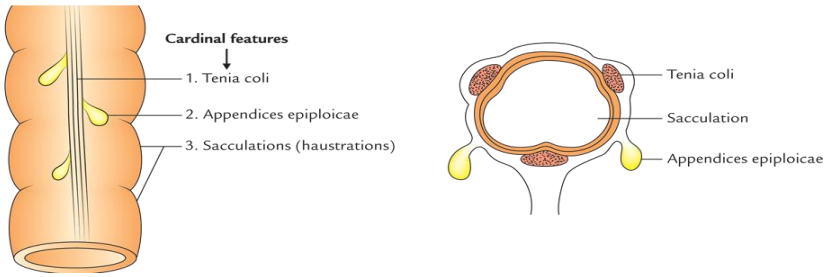

- Presence of taeniae coli which are three ribbon like bands of longitudinal muscle.
- The sacculations are the dilated parts in between the taenia coli.
- The appendices epiploicae are the fat filled bags of visceral peritoneum attached to the taeniae coli.

CAECUM

Caecum is a large blind sac forming the first part of the large intestine. It is situated in the right iliac fossa. It communicate, Superiorly with ascending colon medially with ileum and posteromedially with appendix.

Relations

Anteriorly – coils of intestine and anterior abdominal wall.

Posteriorly – muscles-right psoas and iliacu, genitofemoral, femoral and lateral cutaneous nerve of thigh & Vessels- testicular or ovarian and appendix

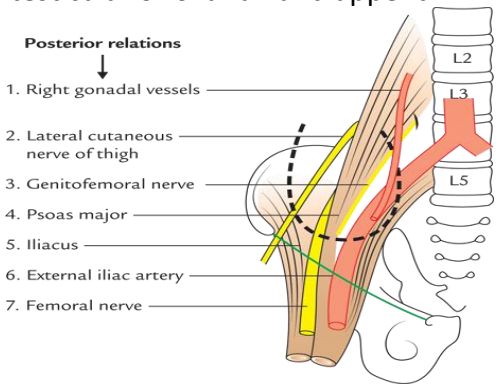

Arterial supply - ileocolic artery.
Venous drainage - into superior mesenteric vein.
Nerve supply → sympathetic → T11 and L1 spinal nerves
Parasympathetic → vagus

Applied anatomy

Caecum is commonly involved in

1. Amoebiasis, causing amoebic dysentry
2. Intestinal tuberculosis
3. Carcinoma

VERMIFORM APPENDIX

This is a worm-like diverticulm arising from the posteromedial wall of caecum.
Position – it is lies in right iliac fossa.
Appendicular orifice - It is situated in the posteromedial aspect of the caecum 2cm below the ileocaecal orifice.

Parts

1. Base – attached to posteromedial wall of caecum.
2. Body – tubular part between base and tip.
3. Tip – it is directed in various directions. On the basis of direction of the tip it is classified into.

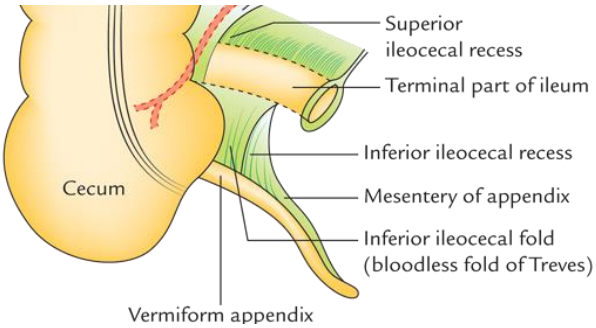

Positions	Direction or Position of appendix
Paracolic or 11 O clock position	The appendix is directed upwards and to the right. It is about 2%.
Retrocaecal or 12 O clock position	Directed upwards and lies behind the caecum or ascending colon. This is the commonest position of appendix. It is about 65%
Splenic or 2 O clock position.	The appendix is directed upwards and to the left. It points towards the spleen. Appendix may be 1. anterior to ilium called preilial 2. Posterior to ilium called postilial
Promonteric or 3 O clock position.	It is directed horizontally and to the left, pointing to the sacral promontory. It is less than 1%.
Pelvic or 4 O clock position.	It descend into the pelvis. It is about 30%
Midinguinal or 6 O clock position.	It is directed vertically downward. Itlies behind the caecum and may point towards the inguinal ligament.

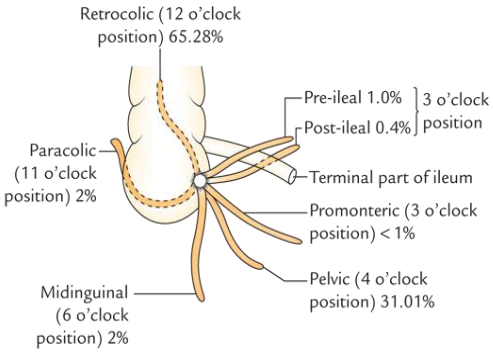

Peritoneal relation – the appendix is suspended by small, triangular fold of peritoneum, called mesoappendix.

Arterial supply- appendicular artery is a branch of the ileocolic artery.

Nerve supply

Sympathetic – derived from T9 and T10 segment of spinal cord.

Parasympathetic- derived from vagus.

Microscopic structure - general plan of git

1. **Mucos**
2 **Submucosa**
3. **Muscularis layer**
4**. serosa**

Applied anatomy

1. Inflammation of the appendix is known as appendicitis. The operation to removal of the appendix is called appen-dicectomy.

Ascending colon

It isabout 12.5 cm long and extends from the caecum to theinferior surface of the right lobe of liver.

Right colic flexure(hepatic flexure of colon)

It is the junction of ascending colon and transverse colon.

Transverse colon

It is about 50cm long and extend across the abdomen from right colic flexure to left colic flexure.

Left colic flexure(splenic flexure)

It is the junction of the transverse colon and descending colon.

Descending colon

It is about 25cm long and extends from the left colic flexure to the sigmoid colon.

Sigmoid colon

It is about 37.5 cm long, and extends from the pelvic brim to the 3rd piece of sacrum, where it become the rectum.

Arterial supply – right, middle and left colicarteries, ileocolic artery, sigmoid artery and superior rectal artery.

Venous drainage – right, middle, left colic and iliocolic vein → superior mesenteric vein → portal circulation .

Other vein → inferior mesenteric vein → portal circulation

Nerve supply – sympathetic T11 to L1

Parasympathetic – vagus

Microscopic structure

1. **Mucosa** is lined by simple columnar cells with microvilli and goblet cells. Villi are absent. Lamina propria filled with intestinal glands called crypts of Lieberkubn. Muscularis mucosae made of inner circular and outer longitudinal layers of smooth muscles.
2 **Submucosa** is made up of loose areolar connective tissue with numerous blood vessels, lymphatics and nerve fibers.
3. **Muscularis externa** consists of inner circular and outer longitudinal smooth muscle layer.
4. **Serosa** is a peritoneal covering made of flat squamous cell.

Difference between Small intestine and Large intestine

Features	Small intestine	Large intestine
Appendix epiploicae	Absent	Present
Taeniae coli	Absent	Present
Sacculations	Absent	Present
Distensibility	Less	More
Fixity	Greater part is freely mobile	Greater part is fixed
Villi	Present	Absent
Transverse mucosal folds	Permanent	Obliterated
Payer's patches	Present in ileum	Absent
Common site for	Intestinal worms, Typhoid & Tuberculosis	Entamoeba histolytica, Dysentry organisms & Carcinoma
Effect of infection & irritation	Diarrhoea	Dysentry

RECTUM

The rectum is the distal part of the large intestine. It is situated between the sigmoid colon and anal canal in the pelvis. Three cardinal features of large intestine are absent.
Situation - posterior part of the lesser pelvis, in front of the lower 3 pieces of sacrum.
Extends – rectosigmoid junction to the anorectal junction.
Lower part dilated to form rectal ampulla.
Course – It runs first downward and backward and finally downwards and forwards.

Relations

1. **Peritoneal relations**
   - Upper 1/3rd of the rectum is covered with peritoneum in front and on sides.
   - Middle i/3rd is covered only in front.
   - Lower 1/3rd is devoid of peritoneum.

2. **Visceral relations**

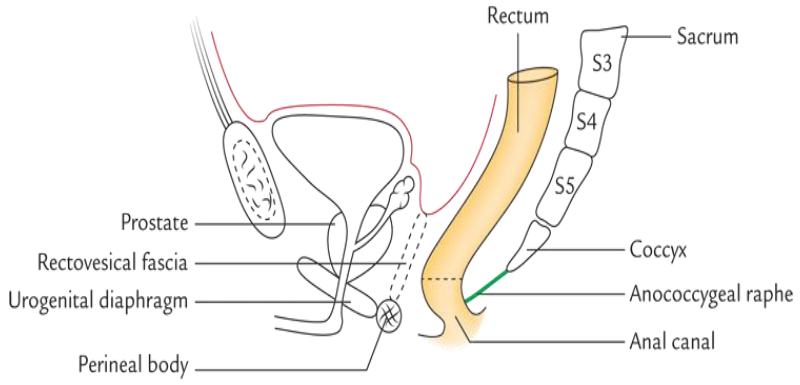

Anterior relations	Male	Female
Upper 2/3rd	rectovesical pouch with coils of small intestine and sigmoid colon.	rectouterine pouch with coils of small intestine and sigmoid colon.
Lower 1/3rd	urinary bldder, terminal part of ureter, seminal vesicles, ductus deferens and prostate.	vagina.

Posterior relations :
sacrum, coccyx, piriformis, levatorani muscles, median and lateral sacral vessels, superior rectal vessels and anococcygeal raphae.
Arterial supply : Superior rectal artery, middle rectal artery and median sacral artery.
Venous drainage : Superior rectal vein, middle rectal vein and median sacral vein
Nerve supply : Sympathetic – L1 and L2 segments of spinal cord.
Parasympathetic – S1, S2 and S3.

Applied anatomy

1. Prolapse of rectum : pelvic diaphragm is weakened can cause prolapse of rectum.
2. Carcinoma of rectum – is common and situated in the rectosigmoid junction.

ANAL CANAL

Anal canal is the terminal part of the large intestine. It lies in between the right and left ischioanal fossae.
Extent – anorectal junction to the anus.

Relations

Anteriorly
In both sex - perineal body.
In male – membraneous urethra and bulb of penis.
In females – lower end of vagina.
Posteriorly : Anococcygeal ligament and tip of coccyx.
Laterally : ischioanal fossae.

Interior of anal canal

It is divided into three parts

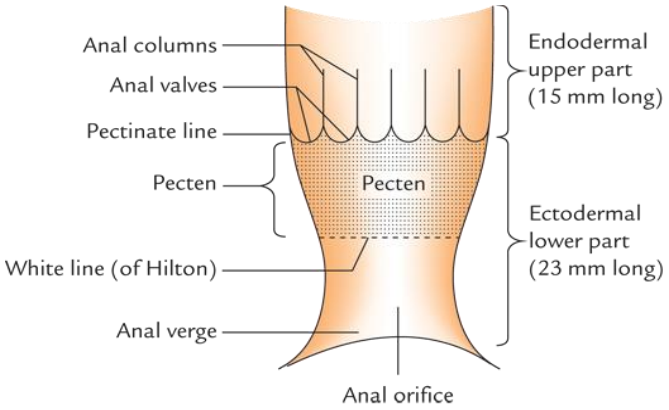

1. **Upper mucous part**
   It is about 15mmlong and lined by mucous membrane. Mucous membrane shows-
- 6 to 10 vertical folds; these folds are called the anal columns of Morgagni.
- Lower end of the anal columns are united to each other by a short transverse folds of mucous membrane called anal valves.
- Above the each valve there is a depression in the mucosa called anal sinus.
- The anal valves together form a transverse line called pectinate line.

2. **Middle part or pectin**

- It is about 15mm long and lined by mucous membrane.
- The mucosa has a bluish appearance because of a dense venous plexus, called pectin.
- The lower limit of pectin has a whitish appearance, is called white line of Hilton.

3. **Lower cutaneous part**

- It is about 8mm long and is lined by skin containing sweat and sebaceous glands.

Anal sphincters

1. **Internal anal sphincter**
   It is involuntary in nature. It is formed by the thickened circular muscle coat. It surrounds the upper three fourth.
2. **External anal sphincter**
   It is voluntary in nature. It is made up of a striated muscle. It surrounds the whole length of the anal canal.

Arterial supply

1. Above the pectinate line – superior rectal artery.
2. Below the pectinate line – ninferior rectal artery.

Venous drainage

Internal rectal venous plexus, external rectal venous plexus and anal veins.

Nerve supply

Above the pectinate line – sympathetic L1 and L2 spinal nerves.
Parasympathetic – S2 to S4 spinal nerves
Below the pectinate line by inferior rectal nerves.

Applied anatomy

1. Piles/ haemorrhoids-
a. Internal piles or true piles are saccular dilatations of the internal rectal venous plexus.
b. External piles or false piles occur below the pectinate line and are, therefore, very painful.
2. Fissure in ano – anal fissure is caused by the rupture one of the anal valve, usually by the passage of dry hard stool in a constipated person.

LIVER

The liver is the largest gland in the body. It is reddish brown in colour.
Location – right and left hypochondrium and epigastrium.
External features
It is wedge shaped. It has five surfaces and one border. Surfaces are - anterior, posterior, superior, inferior and right.
Inferior border – it is sharp and it separates the anterior surface from inferior surface. It consists of two notches - **interlobar notch** for the ligamentum teres and **cyctic notch** for the fundus of the gall bladder.

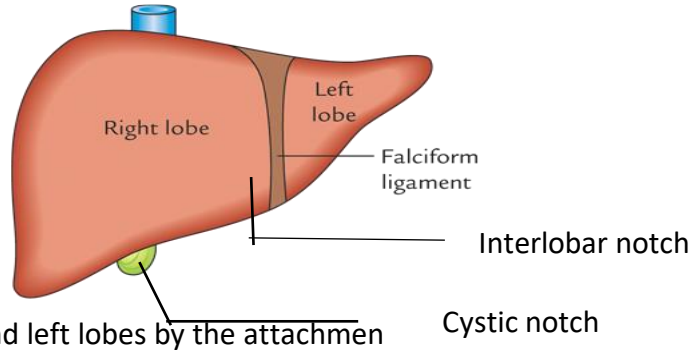

The liver is divided into right and left lobes by the attachmen

- Falciform ligament anteriorly and superiorly.
- Fissure for ligamentum teres inferiorly.
- Fissure for ligamentum venosum posteriorly.

1. **Right lobe**
   It is larger than the left lobe. It consist of caudate lobe and quadrate lobe.
   Caudate lobe
   It is situated on the posterior surface.
   It is bounded -

- Right side by groove for inferior venacava
- Left side by fissure for ligamentum venosum.
- Inferiorly by porta hepatis.

Right lobe of liver is connected in to the caudate lobe by caudate process.
Left side of caudate lobe contain an elevation called papillary process.
Quadrate lobe
It is situated onthe inferior surface and is rectangular in shape.
It is bounded

- Anteriorly - inferior border.
- Posteriorly – porta hepatis.
- Right – fossa for gall bladder.
- Left - Fissure for ligamentum teres.

Porta hepatis

- It is a deep transverse fissure about 5cm long.
- It lies between caudate lobe above and quadrate lobe below.
- Structures passing through - the portal vein, hepatic artery, hepatic plexus of nerves, right and left hepatic duct and lymphatics .

2. **Left lobe**
   Left lobe of the liver is much smaller than the right lobe.

Relations

1. **Peritoneal relations**

   Liver is covered by peritoneum, except triangular bare area on the posterior surface, groove for inferior venacava, groove for ligamentum teres, groove for ligamentum venosum and fossa for gall bladde.

   Visceral relations

   Anterior surface - xiphoid process, anterior abdominal wall and diaphragm.

   Posterior surface-

   1. Bare area is related o the diaphragm.
   2. Groove for inferior venae cava.
   3. Caudate lobe .
   4. Fissure for ligamentum venosum.
   5. Esophageal impression.

   Superior surface - middle cardiac impression and on each side by dome of diaphragm.

   Inferior surface

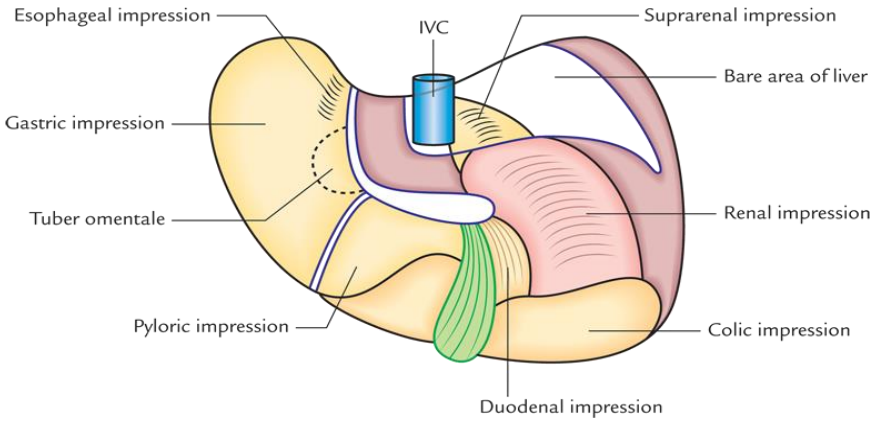

   1. Gastric impression.
   2. Fissure for ligamentum teres.
   3. Lesser omentum,
   4. The pylorus,
   5. First part of duodenum.
   6. Fossa for gall bladder .
   7. Colic impression
   8. Renal impression
   9. Suprarenal impression.

   Right surface - Upper 1/3rd is related to pleura
   Middle 1/3rd is related to costodiaphragmatic recess
   Lower 1/3rd is related to diaphragm

   Blood supply

- 20% blood supply through the hepatic artery
- 80% trough the portal vein

   Lymphatic drainage

   Superficial lymphatics drains into caval, hepatic, paracardinal and celiac lymph nodes.
   Deep lymphatics partly into inferior venaca and partly into hepatic nodes.

   Nerve supply

   Hepatic plexus which contains both sympathetic and parasympathetic or vagal fibers.

   Applied anatomy

Inflammation of liver is referred to as hepatitis .
Under certain condition, example malnutrition, the liver tissue undergoes fibrosis and shrinks. This is called cirrhosis of liver.

Structure of liver

- It is covered by a connective tissue capsule, sends septa inside and divide the paranchyma into lobule.
- Each lobule is hexagonal in shape.
- At the center of the lobule contains a central vein with branching and anastomosing plates of hepatocytes radiating outward. The hepatocytes are seperated by sinusoids.
- At the periphery of the lobule portal triads are present which contain branches of hepatic artery and portal vein withbile ductules.
- Hepatocytes are polyhedral in shape with rounded nuclei. Sinusoids lined by endothelial cells, containing phagocytic macrophages called Kupffer cells.

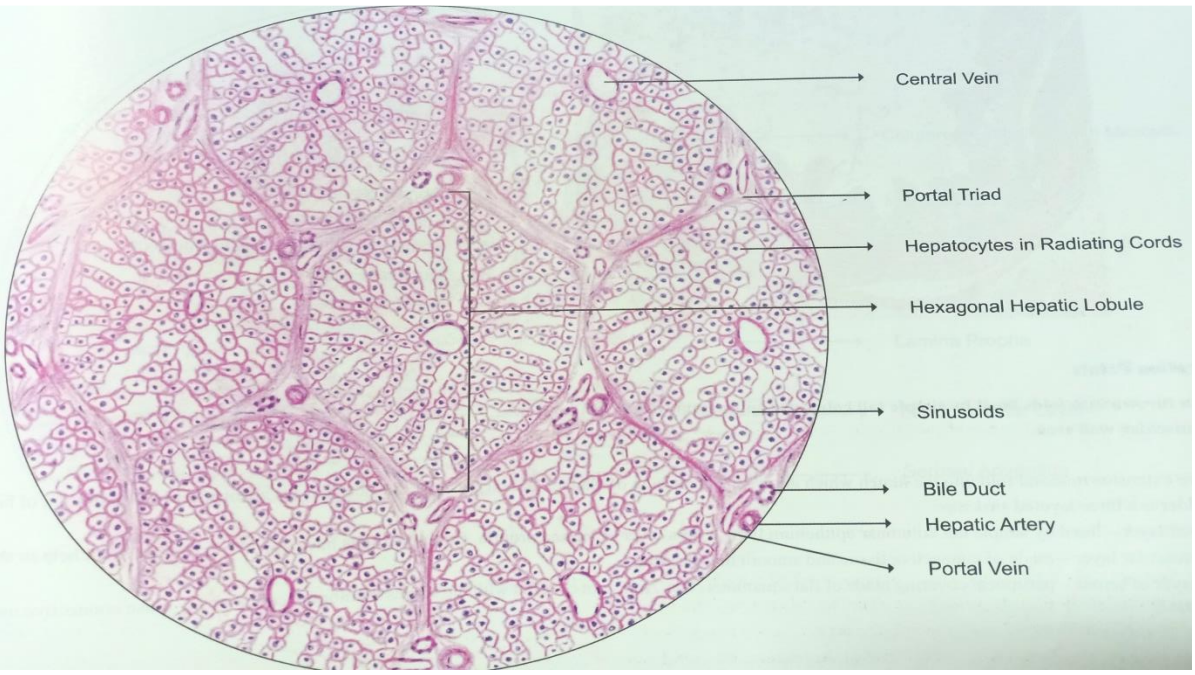

GALL BLADDER

It is a fibrous sac which serves to collect and concentrate the bile.
Location : fossa on the visceral surface of right lobe of liver.
Shape : piriform
Parts : fundus, body and neck.

Parts and relations

Fundus - The anterior end is free, blind and expanded. It lies beyond the inferior margin of the liver and covered by peritoneum.
Body – it lies between fundus and neck. It has two surfaces – upper and lower.
Upper surface is related to inferior surface of liver.
Lower surface is covered by peritoneum, transverse colon and first part of duodenum
Neck – is funnel shaped. Its wall present a dilatation called Hart mann's pouch. It is related to superior duodenal flexure.

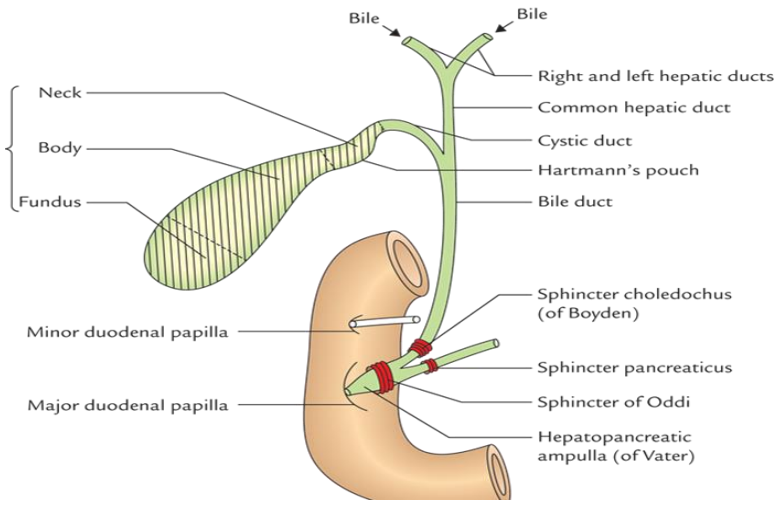

Cystic duct : This duct is spirally curved and joined the the common hepatic duct to form the common bile duct.

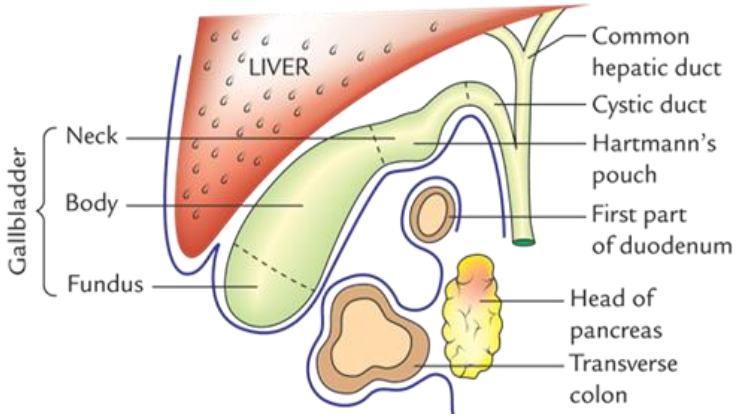

- **Arterial supply** - cystic artery.
- **Venous drainage** – cystic veins which drain into the portal vein.
- **Nerve supply** – cystic plexus of nerves, vagus nerve and right phrenic nerves.
- **Microscopic structure**
  Mucosal layer lined by simple columnar epithelium with microvillai.
  Fibromuscular layer made up of connective tissue & smooth muscles fibers.
  Outer layer of serosa – peritoneal covering made up of flat squamous cells.

- **Applied anatomy**
  1. Cholecystitis – inflammation of gall bladder.
  2. Gall stone

Questions

1. Name the parts of GIT with a neat labeled diagram. Briefly describe Liver, Stomach or Pancreas.
2. Salivary glands (parotid, submandibular and sublingual)
3. Esophagus
4. Stomach
5. Duodenum

6. Caecum
7. Appendix
8. Rectum
9. Anal canal
10. Liver
11. Pancrease
12. Gall bladder
13. Tongue

Difference between

14. Large intestine and small intestine
15. Jejunum and ileum
16. Parotid, submandibular and sublingual salivary glands
17. Constrictions of esophagus and ureter

List the

18. Parts of digestive system
19. Accessory glands of digestive system
20. Parts of large inestine